



EUROPEAN CERTIFIED
HAND THERAPIST

EUROPEAN FEDERATION OF SOCIETIES FOR HAND THERAPY

EFSHT Cheat Card

Interested in becoming an
European Certified Hand Therapist?

www.eurohandtherapy.org
echt@eurohandtherapy.org

Pathology Boutonniere Deformity

Disruption of the central band of the extensor tendon (laceration/closed injury/rheumatoid disease)

- > elongation of triangular ligament
- > lateral bands separate
- > head of the proximal phalanx slips through the gap
- > collateral bands of extensor tendon shift palmarly and cross the joint axis towards flexion side

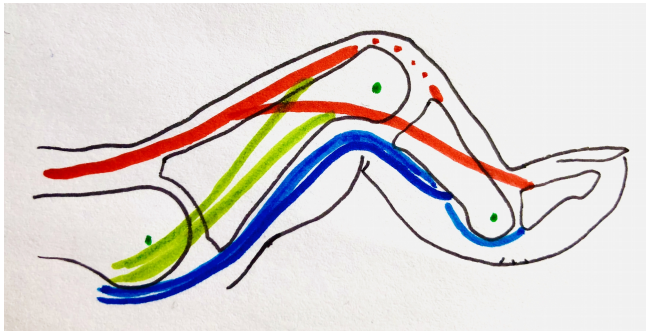
> PIP flexion

All the force of the collateral bands now extend the DIP

> DIP hyperextension

Boutonniere Deformity

Boutonniere: PIP flexion, DIP hyperextension



Central and lateral slip
FDP/FDS

Intrinsic tendons joining extensor hood
Joint axis