



ECHT

EUROPEAN CERTIFIED
HAND THERAPIST

EUROPEAN FEDERATION OF SOCIETIES FOR HAND THERAPY

EFSHT Cheat Card

Interested in becoming an
European Certified Hand Therapist?

www.eurohandtherapy.org
echt@eurohandtherapy.org

Pathology Swan-Neck

Unstable PIP (palmar plate injury, FDS injury, joint destruction in rheumatoid disease, direct trauma etc.)

> loosening of transverse retinacular ligament

> collateral band shift more dorsally/medially

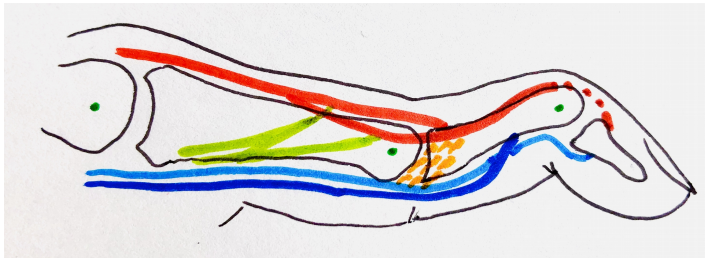
> **PIP hyperextension**

Interruption of terminal tendon of extensor hood (Mallet finger)

> **DIP flexion**

Swan-Neck Deformity

Swan Neck: PIP hyperextension, DIP flexion



Central and lateral slip
Transverse retinacular ligament
Intrinsic tendons joining extensor hood

FDP/FDS
Joint axis